

# Meckel's Diverticulum Fistulating into the Rectum: An Extremely Uncommon Presentation

Raghav Narang\*, Shishir Kumar, Aravindh Radhakrishnan, Prakriti Giri and Yogesh Kumar Sarin

Department of Pediatric Surgery and Pediatric Urology, BLK-MAX Superspecialty Hospital, New Delhi, India

## ARTICLE INFO

### Article history:

Received: 17 January 2023

Accepted: 16 February 2023

### Online:

DOI 10.5001/omj.2024.19

### Keywords:

Meckel Diverticulum;  
Intestinal Obstruction;  
Pediatric Surgery.

## ABSTRACT

An 11-year-old girl presented with an extremely rare complication of Meckel's diverticulum. The patient presented with complaints of abdominal distension, abdominal pain, decreased appetite, and non-bilious vomiting for 20 days with a history of mass protruding per rectum. Examination revealed a distended abdomen and prolapsing bowel loops during rectal examination, resembling intussusception. Radiological findings indicated intestinal obstruction. Surgical exploration revealed Meckel's diverticulum invading the rectum, accompanied by dense inter-bowel adhesions. The patient underwent resection of Meckel's diverticulum and repair of the rectal rent. This case highlights the rarity of Meckel's diverticulum fistulating into the rectum.

Meckel's diverticulum is commonly associated with abdominal pain, gross bleeding per rectum, and gastrointestinal (GI) obstruction. GI obstruction in Meckel's diverticulum typically occurs due to intussusception or twisting of bowel loops. Spontaneous fistulization of Meckel's diverticulum into other parts of the GI tract, such as the bladder, is extremely rare.<sup>1,2</sup> This report describes a case of spontaneous ulceration and fistulization of Meckel's diverticulum into the rectum, presenting as GI obstruction.

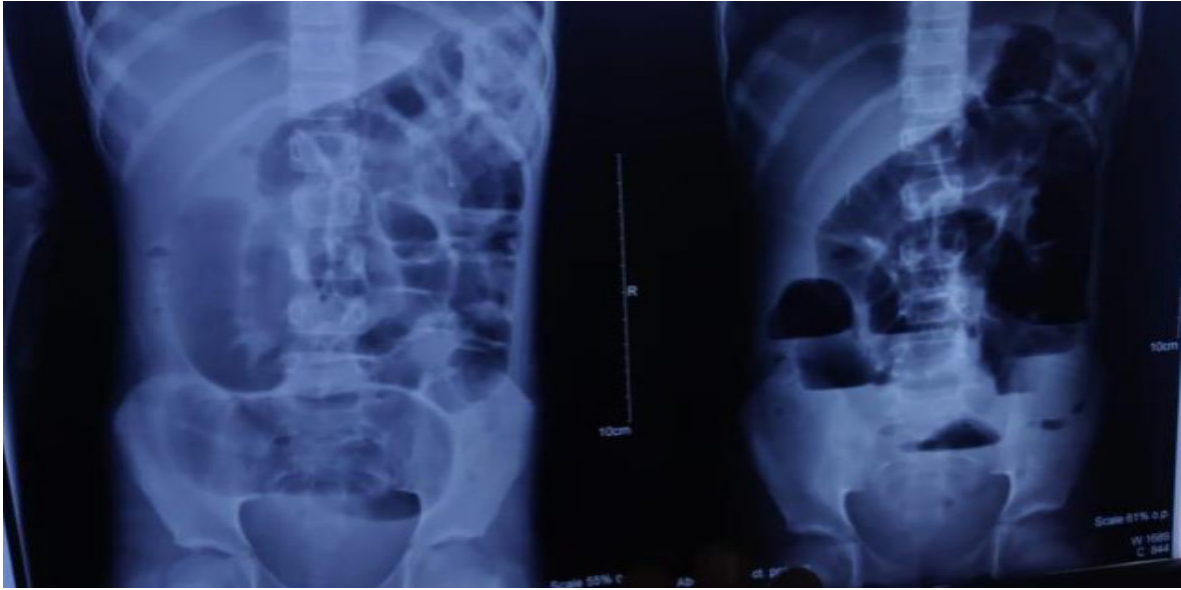
## CASE REPORT

An 11-year-old girl presented with symptoms of abdominal distension, abdominal pain, decreased appetite, non-bilious vomiting for 20 days, and a history of a fleshy mass protruding per rectum. An abdominal examination revealed a soft, distended, non-tender abdomen with no guarding or rigidity. Increased bowel sounds were noted, and rectal examination indicated prolapsing bowel loops resembling intussusception. Abdominal roentgenogram revealed multiple air-fluid levels [Figure 1]. An ultrasound of the abdomen revealed dilated small bowel loops showing to and fro peristalsis with an ill-defined hypoechoic tubular structure in the pelvis closely abutting the rectal

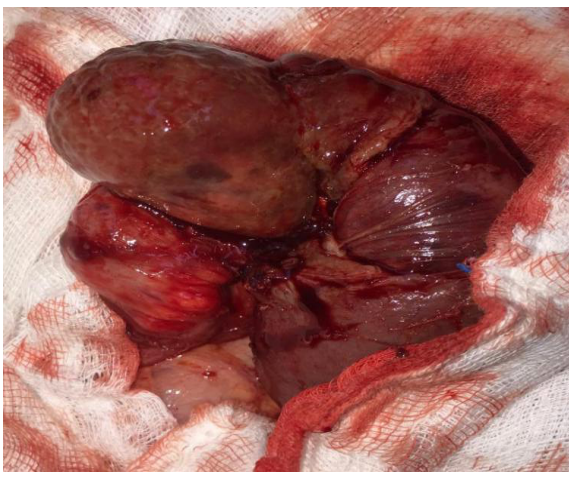
wall, which was seen possibly telescoping into the proximal small bowel suggestive of intussusception. The patient was taken for surgery with a provisional diagnosis of intussusception. Intraoperatively, there was no intussusception but dense inter bowel adhesions in the pelvis, which were meticulously released. The whole small bowel was explored and revealed a normal cecum and appendix. Meckel's diverticulum was found invading the anterior rectal wall with its tip lying within the rectal lumen. The tip of Meckel's diverticulum had fistulated into the rectum, which was felt as prolapsed intussusceptum on rectal examination. The small bowel loops proximal to Meckel's were found to be dilated. Adhesiolysis followed by resection of Meckel's diverticulum was done [Figure 2].

Rectal rent was recognized just above the peritoneal reflection of the rectum [Figure 3] and repaired intra-abdominally using absorbable sutures. A diverting double barrel ileostomy was also fashioned. Histopathology revealed focal ulceration of diverticular epithelium with extensive serositis without any ectopic tissue. A distal loopogram one month later revealed no leak, stricture, or fistula. The patient underwent stoma closure with restoration of bowel continuity and was discharged on full feeds. At six months postoperative follow-up, the child was gaining weight and was complication-free.

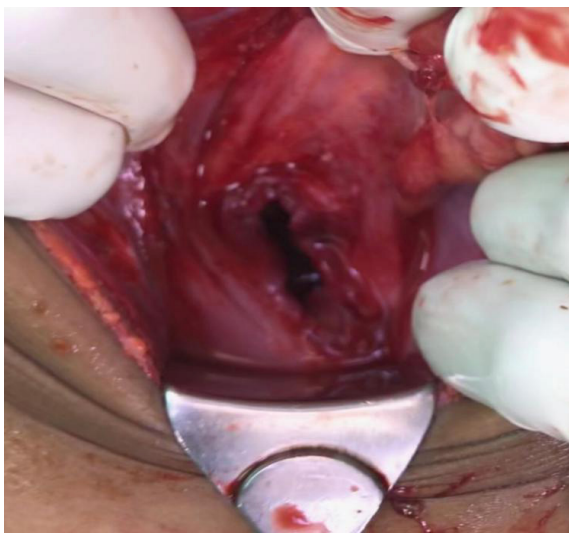
\*Corresponding author: ✉raghavnarang1601@gmail.com



**Figure 1:** Abdominal X-ray showing multiple air fluid levels.



**Figure 2:** Resected Meckel's diverticulum.



**Figure 3:** Rent in the anterior rectal wall.

## DISCUSSION

Meckel's diverticulum is the most common congenital abnormality of the GI tract.<sup>3</sup> Histologically, Meckel's diverticulum is lined mainly by the typical ileal mucosa as in the adjacent small bowel. Bleeding from Meckel's diverticulum due to ectopic gastric mucosa is one of the most common clinical presentations, especially in younger patients.<sup>3</sup>

Meckel's diverticulum results from the failure of obliteration of the omphalomesenteric duct on the antimesenteric border of the terminal ileum that normally disappears between six and eight weeks gestation.<sup>4</sup>

Fistula formation between Meckel's diverticulum and urinary bladder/appendix has been described previously.<sup>1,2</sup> Formation of fistulae between adjacent hollow organs is common in diverticular disease of the colon, but extremely rare.<sup>5</sup> In this case, the Meckel's was found eroding the anterior rectal wall. The aim of the surgical treatment was to resect the inflamed Meckel's diverticulum and close the fistula.<sup>6</sup> Ileal resection is recommended in cases with the adjacent bowel having inflammation.

Enterocolonic fistula, vesicodiverticular fistula, and ileorectal fistula have been reported as well as a fistula between Meckel's diverticulum and the appendix.<sup>2</sup>

An inflammatory attack of Meckel's diverticulum leading to an abscess followed by a fistula could be an etiopathogenesis for the development of a recto-diverticular fistula. The extensive serositis

in the histopathology report points towards active inflammation and a probable cause of fistula formation.

### CONCLUSION

Complications of Meckel's diverticulum fistulating into the rectum have not been reported. In our case, surgical resection, ileostomy, and repair of rectal perforation were done followed by an early stoma closure.

#### *Disclosure*

The authors declared no conflicts of interest. Written consent was obtained from the patient's father.

### REFERENCES

1. Petros JG, Argy O. Enterovesical fistula from Meckel's diverticulum in a patient with Crohn's ileitis. *Dig Dis Sci* 1990 Jan;35(1):133-136.
2. Yang PF, Chen CY, Yu FJ, Yang SF, Chen YT, Kao LC, et al. A rare complication of Meckel's diverticulum: a fistula between Meckel's diverticulum and the appendix. *Asian J Surg* 2012 Oct;35(4):163-165.
3. Sagar J, Kumar V, Shah DK. Meckel's diverticulum: a systematic review. *J R Soc Med* 2006 Oct;99(10):501-505.
4. Mortensen NJ, Jones O. The small and large intestines. In: Williams NS, Bulstrode C, Russell RCG, editors. *Bailey & Love's short practice of surgery*; 2004. p. 1159-1160.
5. Dearden C, Humphreys WG. Meckel's diverticulum: a vesico-diverticular fistula. *Ulster Med J* 1983;52(1):73-74.
6. Cikman O, Kiraz HA, Ozkan OF, Adam G, Celik A, Karaayvaz M. An extremely rare complication of Meckel's diverticulum: enterocutaneous fistulization of umbilical hernia. *Arq Bras Cir Dig* 2015;28(2):152-153.